




Available online at  
**ScienceDirect**  
www.sciencedirect.com

Elsevier Masson France  
**EM|consulte**  
www.em-consulte.com/en



## Letter to the editor

### Laryngocele: An unusual presentation

#### 1. Case report

A 65-year-old, chronic smoker, non-alcoholic, male building worker presented with a 3-month history of progressively deteriorating dysphonia prior to admission with sudden onset of suffocating laryngeal dyspnoea, for which he was tracheotomised.

Clinical examination revealed a patient in good general health, with a mobile larynx and the presence of a firm, painless submandibular swelling. Flexible nasolaryngoscopy demonstrated a mass filling the laryngeal vestibule lined by mucosa with a normal appearance.

Computed tomography demonstrated a tissue density mass occupying the supraglottis and glottis with a fluid level, extending to the pre-epiglottic space with no involvement of the subglottis (Fig. 1).

Direct laryngoscopy demonstrated swelling of the vestibular folds almost totally obstructing the laryngeal lumen lined by mucosa with a normal appearance, in favour of laryngocele.

The mass was resected by open surgery (Fig. 2) with an uneventful postoperative course. Histological examination confirmed the diagnosis of laryngocele and excluded malignancy. The patient presented a favourable outcome with no recurrence after a follow-up of 2 years.

#### 2. Discussion

The laryngocele is a rare entity [1], corresponding to abnormal dilatation of the saccule, communicating with the laryngeal lumen. It is predominantly observed in men in the sixth decade [2].

The aetiopathogenesis of the laryngocele remains poorly elucidated, although several theories have been proposed. Various congenital or acquired factors appear to be involved [2].

Three forms are described according to their site: internal, external and mixed, the most frequent form [1].

The differential diagnosis essentially concerns neck abscess, lymphadenopathy, saccular cysts, branchial cysts and thyroglossal cysts.

Most laryngoceles remain asymptomatic. When they are symptomatic, the signs vary according to the type of laryngocele [3]. The external form presents as a painless and sometimes fluctuating mass in the superior anterolateral triangle of the neck, below the digastric muscle.

Valsalva manoeuvre accentuates perception of the mass, which can be reduced by external pressure, sometimes producing fluid noises [1]. Internal laryngoceles present with dysphonia, dyspnoea, reflex cough or a foreign body sensation [3]. Sudden deterioration of the symptoms is pathognomonic of the mixed form, particularly dyspnoea, due to passage of air from the external to the internal component following compression of the external component [3].

Computed tomography demonstrates a well delimited gas- or fluid-filled mass communicating with the laryngeal ventricle, defines the type of laryngocele and its extension and especially

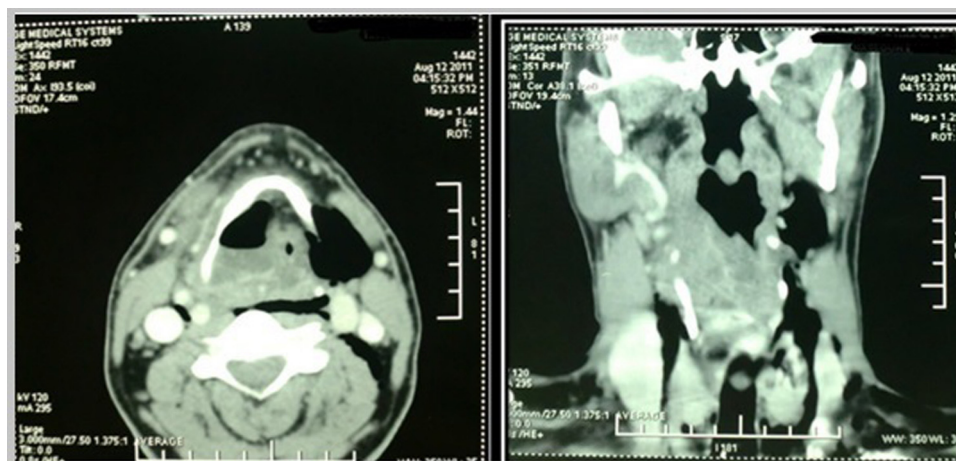
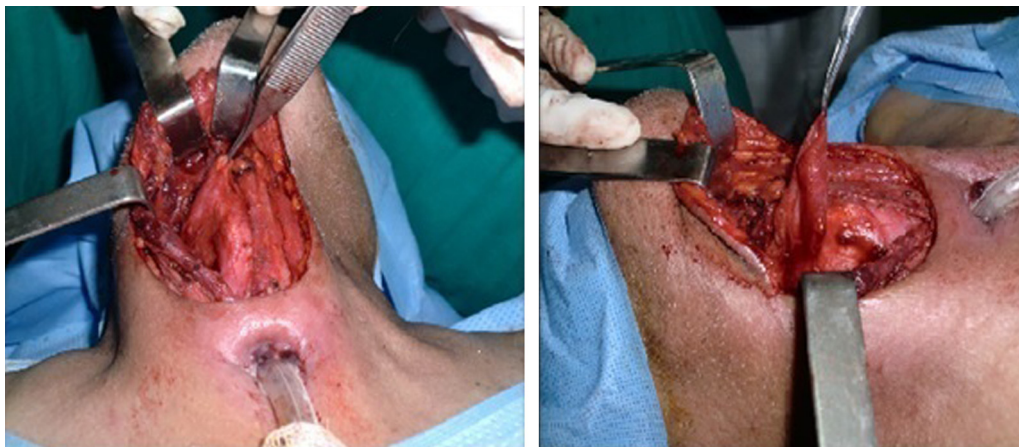

Fig. 1. Computed tomography axial and coronal sections showing the laryngocele.

<http://dx.doi.org/10.1016/j.anorl.2015.03.002>

1879-7296/© 2015 Published by Elsevier Masson SAS.



**Fig. 2.** Intraoperative view: laryngocele dissected as far as its pedicle.

eliminates any predisposing factors, particularly laryngeal cancer, a classical and real association with the laryngocele [1].

Laryngoceles can be complicated by laryngopyocele, pneumonia and exceptionally sudden airway obstruction.

The choice of treatment essentially depends on the size of the lesion. Small laryngoceles can be endoscopically excised with laser, while large internal or external laryngoceles should be removed by an external approach [4].

#### Disclosure of interest

The authors declare that they have no conflicts of interest concerning this article.

#### References

[1] Garrel R, Mondain M, Guerrier B. Kystes du larynx et laryngocèles. In: *EMC Oto-rhino-laryngologie*. Paris: Elsevier Masson SAS; 2009 [20-695-A-10].

[2] Upile T, Jerjes W, Sipaul F, et al. Laryngocele: a rare complication of surgical tracheostomy. *BMC Surg* 2006;14–9.

[3] Vishnu Vardhan Reddy M, Ramakrishna Manish Gupta C, Shobhan Babu A, et al. Laryngocele: a case report and review of literature. *Indian J Otolaryngol Head Neck Surg* 2008;60:281–3.

[4] Marcotullio D, Paduano F, Magliulo G. Laryngopyocele: an atypical case. *Am J Otolaryngol* 1996;17(5):345–8.

Y. Oukessou\*

R.L. Abada

M. Roubal

M. Mahtar

*Service d'ORL, Hôpital 20 Août 1953, CHU Ibn Rochd,  
4, rue Lahcen El Arjoune - ex Dalton, Quartier des  
Hôpitaux, BP 20360, Casablanca, Morocco*

\* Corresponding author.

E-mail address: [dr.oukessou@gmail.com](mailto:dr.oukessou@gmail.com)

(Y. Oukessou)