



Contents lists available at ScienceDirect

## International Journal of Surgery Case Reports

journal homepage: [www.casereports.com](http://www.casereports.com)

# *Histoplasma capsulatum* sinusitis: Possible way of revelation to the disseminated form of histoplasmosis in HIV patients

## Case report and literature review



R. Elansari\*, R. Abada, S. Rouadi, M. Roubal, M. Mahtar

Departement 20 August Hospital Ibn Roched, University Hospital Center Casablanca, Morocco

## ARTICLE INFO

## Article history:

Received 20 December 2015

Received in revised form 26 January 2016

Accepted 10 March 2016

Available online 14 March 2016

## Keywords:

Sinusitis

Disseminated histoplasmosis

Amphotericin B

Immunosuppressed patients

Opportunistic agents

## ABSTRACT

**INTRODUCTION:** *Histoplasma capsulatum* is rarely found in nose and sinuses in immunocompetent and even in immunosuppressed patients. A literature review revealed rare cases of *H. capsulatum* sinusitis and the case we describe in this paper is the first case of *H. capsulatum* sinusitis in Morocco. The purpose of our work is to present a rare case of *H. capsulatum* sinusitis and a literature review.

**CASE REPORT:** A male patient, at his 39 presented to the emergency with suffered from nasal congestion and yellow postnasal rhinorrhea, occasional headaches and epistaxis for over than two months. He had human immunodeficiency virus (HIV) infection for 6 years with failing treatment adherence and he had an opportunistic infection and unconfirmed pulmonary tuberculosis treated 3 years ago.

Computerized tomography from paranasal sinus revealed complete opacification of the ethmoid-maxillary sinuses in the right fossa, consistent with acute sinusitis.

The cultures of the sinus aspirate, skin biopsy, were positive for *H. capsulatum* and the histology of the nasal mucosa and skin biopsy specimen of the rash evoking a sinusitis and cutaneous histoplasmosis.

The patient was started a treatment with intravenous amphotericin B at a rate of 1 mg/kg/day with clear clinical and biological improvement.

**DISCUSSION:** Cultures and histopathologic study confirm histoplasmosis. Itraconazole and amphotericin B are the first line drugs.

**CONCLUSION:** Patients with progressive disseminated histoplasmosis and those with AIDS should be treated with amphotericin B, and the ENT should suspect of opportunistic agents in immunosuppressed patients with sinusitis.

© 2016 The Authors. Published by Elsevier Ltd on behalf of IJS Publishing Group Ltd. This is an open access article under the CC BY-NC-ND license (<http://creativecommons.org/licenses/by-nc-nd/4.0/>).

## 1. Introduction

Sinusitis is a common disease on both adults and children [1], and the most common pathogens cultured from sinus aspirates of patients with sinusitis are streptococcus pneumoniae and non typeable haemophilus influenzae.

Rhinosinusitis occurs from 25% to 30% of patients with AIDS [1]. On those patients we can easily find infections by *Pseudomonas aeruginosa*, fungi, virus, parasites and even mycobacteria. Aspergillus is the main etiological agent of fungal rhinosinusitis, while *Histoplasma capsulatum* is rarely found, in both immune competent and immune depressed patients. In this current study we found a rare case of rhinosinusitis by *H. capsulatum* and we would

like to discuss the aspects related to histoplasmosis pathophysiology, clinical manifestations, diagnosis and treatment.

## 2. Case report

A male patient, at his 39 presented to the emergency of hospital 20 August–Casablanca city of Morocco with suffered from nasal congestion and yellow postnasal rhinorrhea for over than two months. Symptoms were accompanied by occasional headaches and epistaxis. He also presented cacostmia, sudoresis in the afternoon, occasional fever with a weight of 10 kg within the same period. He complained of a cough which produced greenish sputum for several days and noted a skin rash which had been present for three months.

His past medical record was significant, as he had human immunodeficiency virus (HIV) infection for 6 years with failing treatment adherence.

\* Corresponding author.

E-mail address: [dr.elansari66@gmail.com](mailto:dr.elansari66@gmail.com) (R. Elansari).

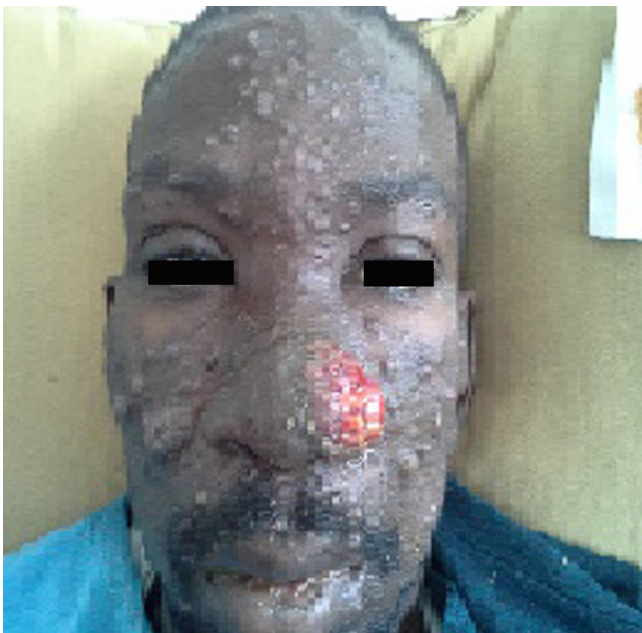


Fig. 1. Papular and nodular rash of the face.

He had an opportunistic infection and unconfirmed pulmonary tuberculosis treated 3 years ago, restraint on clinical arguments and currently he is taking antibacillare treatment.

Physical examination revealed a temperature of 38.5 °C, blood pressure of 86/54 mm Hg, and a pulse rate of 90/min. The respi-

ratory rate was 16/min while abdominal examination revealed a hepatosplenomegaly.

The skin examination was significant for papular and nodular rash of the face (Fig. 1), whose slightly raised edges. CD41 T-lymphocyte count was 120/ml and a virus charge was 310.410 copies. The endoscopic sinus examination was found polypoid and inflammatory nasal mucosa in the right nasal fossa, a stink of the middle meatus, and a bulging posterior wall of the nasopharynx.

Diagnosis discussion revealed: pulmonary tuberculosis, atypical mycobacterium infection, histoplasmosis, sarcoidosis, leishmaniasis or lymphoma.

A chest computerized tomography evidence of bilateral hilar and mediastinal lymphadenopathy and a diffuse reticulonodular infiltrate. There was a 1-cm pulmonary nodule in the superior segment of the right middle lobe (Fig. 2).

Abdominal ultrasound found a hydrocholecyste with expansion of the principal Bilaire way and a splenomegaly with micronodular splenic hilar training. Splenic puncture found a normal splenogramme, the leishmaniasis research was negative and the histological study was inconclusive.

Bone medullary biopsy has not been recovered infiltration of malignant cells. Leishmaniasis sérology was negative, no mark for a leishmaniasis found while doing myelogram and splenogramme.

Computerized tomography from paranasal sinus revealed complete opacification of the ethmoid-maxillary sinuses in the right fossa and partial opacification of both frontal sinuses, consistent with acute sinusitis (Fig. 3). Sinus aspiration and skin biopsy were performed as part of the diagnostic workup. Microscopic examination with gomori methanamine-silver staining showed organisms consistent with histoplasma in both specimens. The cultures of the sinus aspirate, skin biopsy, were positive for *H. capsulatum*. In addition, histology of the nasal mucosa and skin biopsy specimen of the

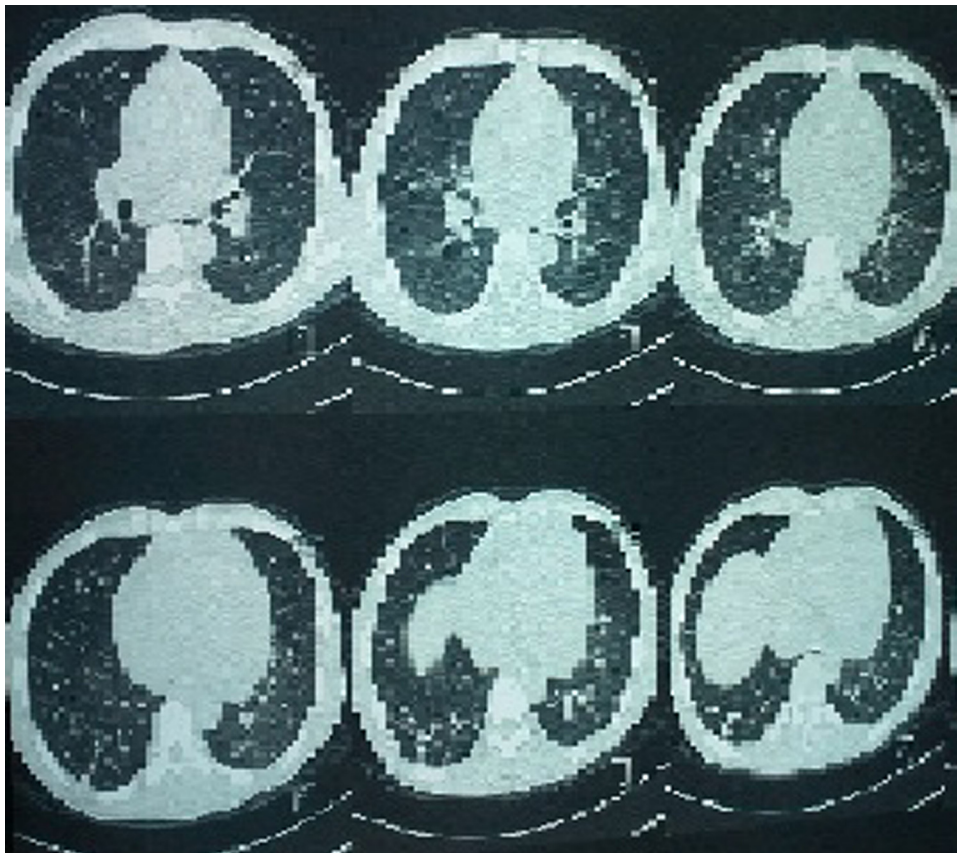


Fig. 2. Bilateral hilar and mediastinal lymphadenopathy and a diffuse reticulonodular infiltrate.

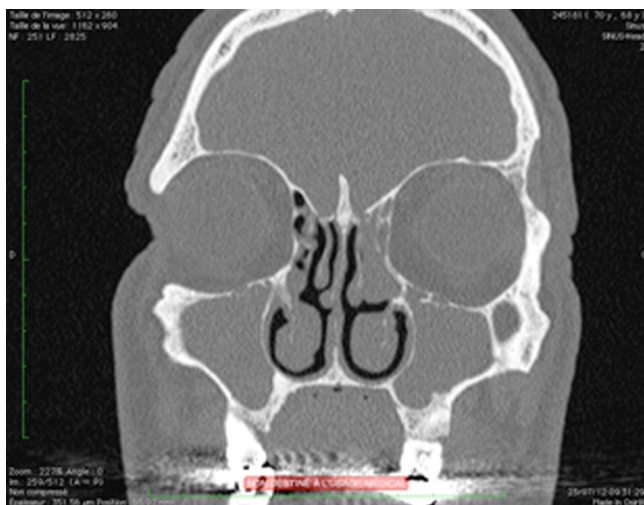


Fig. 3. Complete opacification of the maxillary sinuses bilaterally.

rash showed superficial and deep chronic granulomatous inflammation evoking a sinusitis and cutaneous histoplasmosis.

While awaiting for the results of the above tests, the patient was started a treatment with intravenous amphotericin B at a rate of 1 mg/kg/day (started with gradual dose) with clear clinical improvement (regression until disappearance of skin rash, with decreased spleen) and biological (correction of anemia). Six month after of the treatment, the patient does not develop any nasosinus signs or symptoms.

### 3. Discussion

Recurrent sinusitis has been reported in 25–30% of patients infected with HIV [1,2]. Generally for this kind of patients, such infection tends to be more severe, involves multiple sinuses, and responds less favorably to antibiotic therapy. Increasing immunosuppression, as evidenced by declining CD41 T-lymphocyte counts, tends to be associated with an increasing frequency of infection and infection by otherwise uncommon organisms.

Bacteria, fungi, viruses, parasites, and atypical mycobacteria have all been associated with sinusitis this kind of patients. *P. aeruginosa*, *Staphylococcus aureus*, *aspergillus* spp., *rhizopus* spp., *Cryptococcus neoformans*, cytomegalovirus, microsporidia, *mycobacterium avium*, *mycobacterium intracellulare*, and *mycobacterium kansasii* represent the atypical pathogens reported to cause sinusitis in patients with AIDS [3,4]. Most cases of fungal sinusitis in patients with AIDS are caused by *aspergillus* species, which account for up to 81% of such cases [1,3].

*H. capsulatum* is a very rare cause of sinusitis. A medline database search revealed a little case of *H. capsulatum* sinusitis in a patient with AIDS [4], while no such case in an immunocompetent patient has been reported, to our knowledge. Accordingly, the case we describe in this paper is the first case of *H. capsulatum* sinusitis in Morocco. We consider that sinusitis occurred as a result of disseminated disease leading to seeding of the sinuses, possibly through the hematogenous route [3].

The diagnosis of fungal sinusitis in immunosuppressed patients, like those with AIDS, usually requires an invasive procedure [4]. Because morbidity and mortality are high in those kind of patients, the etiologic agent should be promptly identified and treated [5]. Cultures of sinus aspirates and histopathological examination of biopsy specimens with appropriate staining are cornerstones of the diagnostic algorithm. Evidence of dissemination should be sought with appropriate tests.

The optimal treatment of *H. capsulatum* sinusitis is not known, since reported studies did not include enough patients to allow us to make recommendations. Patients with progressive disseminated histoplasmosis and those with AIDS should be treated with amphotericin B.

The role of itraconazole in these cases is currently being investigated. Anecdotal reports suggest that itraconazole may be an attractive option in mild to moderate disease because of its oral administration, lower costs, and lower toxicity [1]. Patients with AIDS and disseminated histoplasmosis should receive maintenance therapy with itraconazole after induction treatment with amphotericin B, a regimen which has been shown to be safe and effective in this setting [6].

### 4. Conclusion

Based on the present case, we think that treatment of primary *H. capsulatum* sinusitis may be undertaken with high-dose itraconazole if the patient is not severely ill and is able to tolerate the medicine. If the patient is unstable or critically ill, standard treatment with amphotericin B should be promptly initiated, followed by long-term maintenance therapy with itraconazole when the patient's condition permits. However, this is an isolated case, upon which generalizations should not be made. More studies are needed to determine the most appropriate treatment regimen for this disease.

### Conflicts of interest

Non-conflict of interest were clearly specified.

### Funding

Funding source staff.

### Ethical approval

Given approval.

### Consent

Written informed consent was obtained from the patient for publication of this case report and accompanying images.

### Author contribution

R. Elansari: Concept, design, data collection, data analysis, writing the paper.

R. Abada: Concept, design, data collection, data analysis, writing the paper.

S. Rouadi: Concept, design, data collection, data analysis, writing the paper.

M. Roubal: Concept, design, data collection, data analysis, writing the paper.

M. Mahtar: Concept, design, data collection, data analysis, writing the paper.

### Guarantor

El Ansari Rachid.

### References

- [1] A. Zida, *J. Med. Mycol.* 25 (2) (2015) 159–162.
- [2] C. Kauffman, Fungal infections in older adults, *Clin. Infect. Dis.* 33 (15) (2001) 550–555.
- [3] R. Kurowski, M. Ostapchuk, Overview of histoplasmosis, *Am. Fam. Physician* 66 (12) (2002) 2247–2252.
- [4] Mandell Principles and Practice of Infectious Diseases, eighth ed., vol. 2, 2015, pp. 2949–2962.
- [5] J.F. Morpeth, N.T. Rupp, W.K. Dolen, J.P. Bent, F.A. Kuhn, Fungal sinusitis: an update, *Ann. Allergy Asthma Immunol.* 76 (1996) 128–140.
- [6] E. Jane, *Canine Feline Infect. Dis.* (2014) 587–598.

#### Open Access

This article is published Open Access at [scimedirect.com](http://scimedirect.com). It is distributed under the [IJSCR Supplemental terms and conditions](#), which permits unrestricted non commercial use, distribution, and reproduction in any medium, provided the original authors and source are credited.